

## special report

# Pulmonary Embolism: What Have We Learned Since Virchow?\*

## Natural History, Pathophysiology, and Diagnosis

James E. Dalen, MD, MPH, Master FCCP

(*CHEST* 2002; 122:1440–1456)

**Key words:** acute cor pulmonale; pulmonary embolism; pulmonary infarction; venous thromboembolism; venous thrombosis

**Abbreviations:** DVT = deep venous thrombosis; ELISA = enzyme-linked immunosorbent assay; FSP = fibrin split product; P(A-a)O<sub>2</sub> = alveolar-arterial oxygen pressure difference; PIOPED = Prospective Investigation of Pulmonary Embolism Diagnosis; SVCT = spiral volumetric CT; TEE = transesophageal echocardiography;  $\dot{V}/\dot{Q}$  = ventilation/perfusion; VTE = venous thromboembolism

Rudolf Virchow, the brilliant 19th century pathologist, was the first to recognize that blood clots in the pulmonary artery originate as venous thrombi. He stated: “The detachment of larger or smaller fragments from the end of the softening thrombus which are carried along by the current of blood and driven into remote vessels. This gives rise to the very frequent process on which I have bestowed the name of Embolia.”<sup>1</sup>

All discussions of the pathogenesis of deep venous thrombosis (DVT) begin with Virchow’s triad as follows: hypercoagulability; stasis; and injury to the vessel wall.<sup>2</sup> If one examines the commonly accepted risk factors for venous thromboembolism (VTE),<sup>3,4</sup> nearly all fall into one or more of these categories, as shown in Table 1.

The most important risk factor for VTE is inherited or acquired hypercoagulability. The first three inherited coagulopathies to be discovered (antithrombin III deficiency,<sup>5</sup> protein C deficiency,<sup>6</sup> and protein S deficiency<sup>5</sup>) are uncommon in the general population and are infrequent in patients with VTE (2 to 5%).

However, as shown in Table 2, the five most recently discovered hypercoagulable states are far more frequent in the general population. Hypercoagulable states are now recognized in > 25% of patients with VTE.<sup>7</sup> The incidence of hypercoagulable states is even higher in patients with idiopathic VTE and in patients with recurrent VTE.<sup>8</sup>

With time, we will discover additional genetic defects that lead to hypercoagulability, such that the majority of patients with VTE will be found to have a hypercoagulable state. The commonly accepted risk factors for VTE (Table 1) act as precipitants of VTE in patients who have an underlying hypercoagulable state. For example, a 1995 study<sup>9</sup> demonstrated that women with inherited clotting defects have a 9-fold to 19-fold increase in VTE if they use oral contraceptive agents.

If these speculations are correct, the detection of a hypercoagulable state<sup>10–15</sup> could lead to a more focused approach to VTE prophylaxis. Prophylaxis would be directed to those patients with hypercoagulability when they are exposed to one of the precipitants of (*ie*, risk factors for) VTE, such as surgery, trauma, cancer, and pregnancy.

Even better, it might be possible to utilize gene therapy or other procedures to permanently eliminate the hypercoagulable state. If this were to be possible, the incidence of VTE could be decreased markedly, saving thousands of lives, and saving millions of dollars that currently are spent for the diagnosis and treatment of VTE. Further review articles on pulmonary embolism might not be needed.

### NATURAL HISTORY OF DVT

In a landmark article in 1969, Kakkar et al<sup>16</sup> delineated the natural history of VTE in patients undergoing surgery without prophylaxis. The fibrinogen uptake test was utilized to detect postoperative DVT in 132 patients. DVT, confirmed by venography, occurred in 40 patients (30%). DVT began in

\*From the University of Arizona, Tucson, AZ. Presented as the College Medalist Lecture at the annual meeting of the American College of Chest Physicians, October 23, 2000. Manuscript received August 8, 2001; revision accepted April 4, 2002.

Correspondence to: James E. Dalen, MD, MPH, Master FCCP, 1840 East River Rd, Suite 207, Tucson, AZ; e-mail: jamesdalen@yahoo.com

**Table 1—Risk Factors for VTE**

Risk Factors*	Hypercoagulability	Stasis	Trauma
Previous VTE	✓		
Major surgery		✓	✓
Cancer	✓	✓	
Obesity		✓	
Trauma			✓
Fracture (hip or leg)		✓	✓
Pregnancy	✓	✓	
Myocardial infarction		✓	
Congestive heart failure		✓	
Stroke		✓	
Estrogen therapy	✓		
Prolonged immobilization		✓	
Burns		✓	

\*From Anderson et al.<sup>3</sup>

the calf in the majority of patients, and thrombi lysed spontaneously in 14 of the 40 patients. Of the remaining 26 patients, the thrombi remained in the calf and did not extend into the popliteal or femoral veins in 17 patients. In nine patients, the thrombi extended into the popliteal or femoral veins, and pulmonary embolism occurred in four of these nine patients. These findings were subsequently confirmed by additional studies. We now recognize that the risk of fatal pulmonary embolism is dependent on the risk of calf vein thrombosis. Without treatment, approximately 20 to 25% of calf vein thrombi extend into the popliteal and femoral veins, causing proximal DVT. Without treatment, approximately half of patients with proximal DVT develop pulmonary embolism as shown in Table 3.<sup>17</sup>

#### NATURAL HISTORY OF PULMONARY EMBOLISM

In a study from the Dexter Laboratory in 1975,<sup>18</sup> the annual incidence of pulmonary embolism per year in

**Table 2—Inherited and Acquired Hypercoagulable States\***

Variable	Prevalence in General Population	Prevalence in Patients With VTE
Protein C deficiency	0.1–0.3	2–5†
Protein S deficiency	0.3†	2‡
Antithrombin III deficiency	0.5	1‡
Factor V Leiden	4–6	20–25
Prothrombin G-A <sup>20210</sup> gene variant	2§	8§
↑ Factor XI (> 90th percentile)	10	19
↑ Factor VIII (> 1,500 IU/L)	11	25
Hyperhomocystinemia	5	12

\*Values given as %.

†From Dahlback.<sup>10</sup>

‡From Thomas and Roberts.<sup>5</sup>

§From Margaglione et al.<sup>12</sup>

**Table 3—Probability of VTE Without Prophylactic Therapy\***

Variable	Acute MI	Hip Fracture
DVT of calf vein†	25	60
Proximal DVT‡	5	12
PE	2–3	6

\*Values given as No. of cases per 100 patients. MI = myocardial infarction; PE = pulmonary embolism.

†Of these patients, 20% progress to proximal DVT.

‡Of these patients, 50% develop PEs.

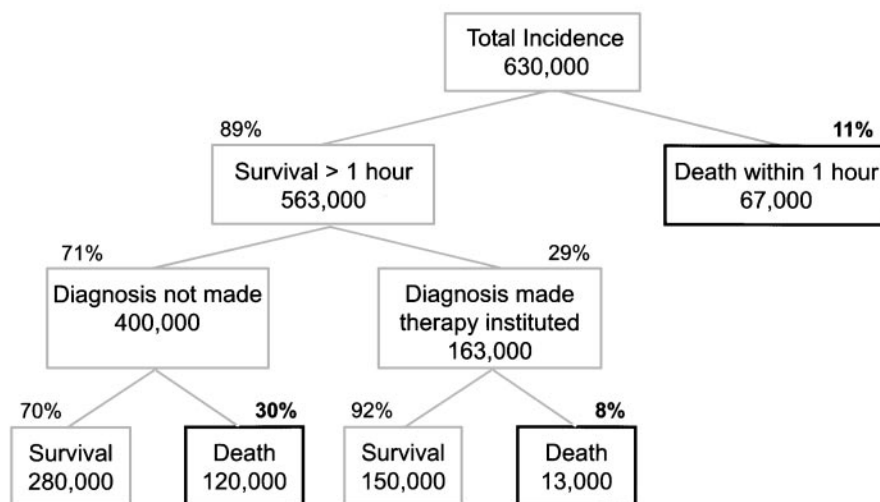
the United States was estimated to be 630,000. It estimated that pulmonary embolism is the major cause of 100,000 deaths, and contributes to 100,000 other deaths in patients with serious coexisting diseases such as heart disease and cancer.<sup>18</sup>

As shown in Figure 1, we estimated that 11% of patients with acute pulmonary embolism die within 1 h and, therefore, do not receive therapy. Of the 563,000 patients who survive at least 1 h, the diagnosis is established and treatment is initiated in only 29%. Most of these patients (92%) survive. The majority of deaths occur among the 400,000 patients in whom pulmonary embolism is not diagnosed or treated. Of the 200,000 patients who die of pulmonary embolism, only 13,000 die because of a lack of response to treatment. The vast majority of patients (187,000) die because of a failure of diagnosis.

In re-examining these estimates 25 years later, what would we change? The mortality rate of patients treated for pulmonary embolism has decreased from 8%<sup>19</sup> to < 5%.<sup>20,21</sup> The number of patients in whom pulmonary embolism is diagnosed and treated is an important variable in these estimates. Our 1975 estimate of 163,000 cases<sup>18</sup> is consistent with an estimate of 197,000 patients discharged from the hospital with a diagnosis of pulmonary embolism in 1975 by Gillum.<sup>22</sup> He reported a marked decrease (40%) to 120,000 cases in 1985. It is unlikely that the percentage of patients dying of massive pulmonary embolism within 1 h has changed, and there are no studies to indicate that the percentage of patients with pulmonary embolism who receive a diagnosis and are treated has changed.

The principal point of the report<sup>18</sup> was that the majority of deaths due to pulmonary embolism (*ie*, > 90%) occur in patients who are not treated because the diagnosis is not made. Less than 10% of all pulmonary embolism deaths occur in patients in whom treatment is initiated. Improved treatment will have a minimal impact on the number of deaths due to pulmonary embolism. Improved diagnosis, and most importantly, more effective prevention of DVT present the greatest opportunities to prevent fatal pulmonary embolism.

## Incidence of Pulmonary Embolism Per Year in the United States



*Progress in Cardiovascular Diseases, Vol. XVII, No. 4 (January/February), 1975*

FIGURE 1. Of an estimated 200,000 deaths per year in the United States, only 13,000 (6%) occur in patients who have received treatment. The vast majority of patients (94%) who die of pulmonary embolism do not receive treatment because the diagnosis is not made. Reproduced with permission by Dalen and Alpert.<sup>15</sup>

### DIAGNOSIS OF DVT

The clinical diagnosis of DVT is unreliable because the majority of patients with DVT are asymptomatic and do not have clinical findings. In the Prospective Investigation of Pulmonary Embolism Diagnosis (PIOPED) study<sup>23</sup> of 251 patients with angiographically documented pulmonary embolism, only 11% had evidence of DVT by physical examination. The two most common findings, edema and calf tenderness, are not specific for DVT. The most specific finding, unilateral leg edema, occurs in < 10% of patients.<sup>24</sup> Objective tests are required for the accurate diagnosis of DVT.

A landmark article by Rabinov and Paulin<sup>25</sup> in 1972 described a technique for venography of the lower extremities that reliably visualizes the venous system of the lower extremities. DVT can be recognized by the presence of constant filling defects, abrupt cutoffs, nonfilling of the entire deep system, or portions thereof, and/or demonstration of collateral flow.

Venography became the “gold standard” for the diagnosis of DVT just as selective pulmonary angiography became the “gold standard” for the diagnosis of pulmonary embolism. As in the case of pulmonary angiography, venography is an invasive procedure that is not readily available at all hospitals. A number of noninvasive tests for DVT have been developed that have been validated by comparison to venography, the “gold standard.”

Hull et al<sup>26</sup> compared the results of <sup>125</sup>I fibrinogen scanning and impedance plethysmography to venography in 219 patients with suspected DVT. The results of one or both tests (*ie*, <sup>125</sup>I fibrinogen scanning and impedance plethysmography) were positive in 94% of patients who had positive venogram findings. The results of both tests were negative in 91% of patients with negative venogram findings.

Compression ultrasonography has been found to be an accurate method with which to detect proximal DVT. In a review of five studies comparing the results of compression ultrasonography to venography in 475 patients, Polak<sup>27</sup> reported a sensitivity of 95.2% and a specificity of 98.6%. Compression ultrasonography is less sensitive in detecting DVT below the knee, and its sensitivity has been reported to be only 62% in patients with silent DVT.<sup>28</sup>

The ability to reliably diagnose asymptomatic DVT by venography or a noninvasive test has had the following benefits:

1. The demonstration that most patients with pulmonary embolism have associated DVT has helped to clarify that DVT and pulmonary embolism are manifestations of the same disease (VTE).
2. It has defined which patients with suspected DVT require therapy and which do not.
3. Follow-up studies have led to a better understanding of the natural history of DVT.

- In patients with suspected pulmonary embolisms in whom lung scan findings have been inconclusive, the determination of the presence or absence of DVT helps to determine which patients require therapy.

#### CLINICAL RECOGNITION OF PULMONARY EMBOLISM

Virchow's<sup>1</sup> only mention of the clinical findings in cases of pulmonary embolism was that "in the case of very large fragments even the principal trunks of the pulmonary artery are blocked up and instantaneous asphyxia occurs."

It is well-recognized that the signs and symptoms of pulmonary embolism are nonspecific and that, as a result, the clinical recognition of pulmonary embolism is notoriously inaccurate. The lack of sensitivity of the clinical diagnosis of pulmonary embolism is evident from postmortem studies<sup>29</sup> demonstrating that the majority of cases of pulmonary embolism detected postmortem were not diagnosed (or treated) prior to death. The sensitivity of the clinical recognition of pulmonary embolism could be as low as 25%, as shown in Figure 1. Of an estimated 630,000 patients per year who have pulmonary embolism, the diagnosis was made and treatment initiated in only 163,000 patients (25%).

The lack of specificity of the clinical diagnosis became evident when pulmonary angiography became available as a "gold standard" for the diagnosis of pulmonary embolism during life. An early report<sup>30</sup> from the Dexter Laboratory in 1971 noted that the diagnosis of acute pulmonary embolism was confirmed in only 45% of 247 patients undergoing pulmonary angiography for suspected pulmonary embolism. A later report from the PIOPED Study<sup>23</sup> noted that the clinical diagnosis of pulmonary embolism was confirmed in only 33% of 755 patients undergoing pulmonary angiography.

In the PIOPED report,<sup>23</sup> clinicians were asked to rate the probability of pulmonary embolism prior to obtaining a ventilation/perfusion ( $\dot{V}/\dot{Q}$ ) scan or pulmonary angiography. They rated the probability of pulmonary embolism to be 80 to 100%, 20 to 79%, or 0 to 19%. As shown in Table 4, when the clinical suspicion of pulmonary embolism was very high (*ie*, 80 to 100% probability), most patients (68%) did have pulmonary embolism. When the clinical suspicion was very low (*ie*, <20% probability), few patients (9%) had pulmonary embolism. However, pulmonary embolism was very strongly suspected in only 10% of the cases, and the suspicion of pulmonary embolism was very low in only 26%. In the majority of cases (64%), the clinical probability was

**Table 4—Clinical Diagnosis of Pulmonary Embolism vs Angiographic Diagnosis\***

Clinical Probability of PE Prior to $\dot{V}/\dot{Q}$ Scan or Pulmonary Angiography	PE Documentation	
	Clinical Diagnosis	Pulmonary Angiography
80–100	10	68
20–79	64	30
0–19	26	9

\*Values given as %. See Table 3 for abbreviations not used in the text.

judged to be uncertain (20 to 79%). The incidence of pulmonary embolism was 30% in those with an uncertain clinical diagnosis of pulmonary embolism. Of the 251 patients with angiographically documented pulmonary embolism, the clinical suspicion of pulmonary embolism had been high (*ie*, 80 to 100%) in only 61 patients (24%).<sup>23</sup> Two algorithms that have been described for the clinical diagnosis of PE<sup>30,31</sup> result in a larger number of patients with low pretest probability of PE (49%<sup>31</sup> and 57%<sup>32</sup>) compared to the PIOPED report,<sup>23</sup> in which only 26% of patients had a low clinical probability of PE. However, the percentage of patients with a high probability of PE was not improved (6%<sup>31</sup> and 7%<sup>32</sup>) compared to a probability of 10% in the PIOPED study.<sup>23</sup>

The percentage of patients with confirmed PE in these two reports<sup>31,32</sup> who had a high pretest probability of PE was 17% in the report by Wells et al<sup>32</sup> and 28% in the report by Wicki et al,<sup>31</sup> compared to 24% in the PIOPED report.<sup>23</sup> These two algorithms help to exclude the diagnosis of PE, but they have not improved the pretest identification of patients with confirmed PE.

One reason for the inaccuracy of the clinical diagnosis of pulmonary embolism is the fact that pulmonary embolism can present as three different syndromes (pulmonary infarction, acute cor pulmonale, or acute unexplained dyspnea).<sup>31</sup> These three syndromes are quite different in their clinical presentation, and each syndrome has distinct clinical and laboratory findings.

#### SYNDROMES OF ACUTE PULMONARY EMBOLISM

##### *Pulmonary Infarction/Hemorrhage*

Virchow<sup>34</sup> was the first to note that pulmonary embolic obstruction can lead to pulmonary infarction, which is defined as the necrosis of lung tissue distal to the site of embolic obstruction. He was also the first to note that pulmonary embolism can occur without resultant pulmonary infarction.<sup>34</sup> Cohnheim

and Litten<sup>35</sup> in 1875 were the first to demonstrate experimentally that embolism can cause pulmonary infarction.

### *Which Pulmonary Embolism Patients Develop Pulmonary Infarction?*<sup>9</sup>

Pathologic studies in the late 19th and in the 20th century reported that pulmonary infarction was a rare complication of pulmonary embolism in the absence of passive congestion of the lungs. Experimental studies by Karsner and Ash in 1912<sup>36</sup> demonstrated that embolism of a healthy lung does not cause “true” infarction. That is, necrosis of the alveolar walls did not occur unless pulmonary venous pressure was increased by ligation of the pulmonary vein of the lobe that has been embolized. However, the authors noted that emboli to a healthy lung lead to intra-alveolar hemorrhage without necrosis.

Chapman et al in 1949<sup>37</sup> used autologous blood clots to induce pulmonary embolisms in dogs. As with Karsner and Ash,<sup>36</sup> they found that pulmonary embolism did not lead to necrosis of lung tissues in dogs with healthy lungs. However, if the dogs were pretreated with  $\alpha$ -naphthylthiourea, an agent that causes pulmonary congestion and edema, true infarction with alveolar necrosis occurred.

Hampton and Castleman,<sup>38</sup> in their pioneering studies reported in 1940 correlating postmortem chest radiographs with autopsy findings in 400 patients, were the first to describe “incomplete pulmonary infarction,” that is, intra-alveolar hemorrhage without necrosis of the alveolar walls. They noted that this is the most frequent finding in the first 2 days of infarction. After 2 days, necrosis of the alveolar walls begins and leads to true pulmonary infarction, which leads to an organized healed scar.

Hampton and Castleman<sup>38</sup> noted that incomplete infarction may cause a roentgen shadow that disappears completely in 2 to 4 days, which is consistent with resolution of the intra-alveolar hemorrhage instead of the organization of the lesion. They concluded that pulmonary infarction begins as incomplete infarction, that is, a hemorrhage without necrosis. In patients with healthy lungs, the infarction remains incomplete and resolves, and the pulmonary infiltrate disappears. In patients with congestive heart failure, the infarction goes on to necrosis, resulting in true pulmonary infarction with a scar and persistent radiograph findings. The authors also noted that patients with incomplete infarction without coexistent heart disease were unlikely to die, and therefore were less likely to be examined at postmortem.

The findings and observations of Hampton and Castleman<sup>38</sup> help to explain the discrepancy between

pathologists and clinicians with regard to whether pulmonary infarction can occur in patients without prior heart disease.

A study from the Dexter Laboratory<sup>39</sup> evaluated the signs and symptoms of pulmonary infarction in patients with acute pulmonary embolism documented by pulmonary angiography. They defined pulmonary infarction as the presence of an infiltrate (as determined by radiograph) and pleuritic pain in an area of the lung with angiographically documented pulmonary embolism. Forty-one of 124 patients (33%) with documented pulmonary embolism met this clinical definition of pulmonary infarction. Only 18 of these 41 patients had associated heart disease. The majority of the 41 patients with pulmonary infarction had submassive pulmonary embolism with obstruction of the distal branches of the pulmonary circulation.

Follow-up chest radiographs in these patients with clinical evidence of pulmonary infarction were quite different in those who did or did not have associated heart disease. In 14 patients with prior heart disease, the infiltrate cleared within 7 days in only one patient and persisted for more than 2 weeks in nine patients. In the 23 patients without associated heart disease, the infiltrate cleared within 1 week in 10 patients and persisted for more than 2 weeks in only three patients. These findings support the observations of Hampton and Castleman<sup>38</sup> with regard to incomplete infarction. The pleuritic pain, hemoptysis, and pulmonary infiltrate are due to pulmonary hemorrhage (*ie*, intra-alveolar hemorrhage). In patients without heart disease with normal pulmonary venous pressure, the hemorrhage resolves, the pulmonary infiltrate disappears, and true pulmonary infarction with necrosis of lung tissue does not occur. These patients with submassive pulmonary embolism rarely die and therefore are not examined by pathologists. In patients with prior heart disease, especially those with congestive heart failure, the pulmonary hemorrhage progresses to infarction with the necrosis of lung tissue. The pulmonary infiltrate persists as the infarction undergoes organization. The patients with coexistent heart disease are more likely to die of submassive pulmonary embolism, and therefore are more likely to be studied postmortem.

The angiographic evidence of submassive embolism with obstruction of subsegmental branches of the pulmonary circulation, as opposed to obstruction of the central pulmonary circulation, in patients with pulmonary infarction is consistent with Virchow's observation that ligation of the main right pulmonary artery does not lead to pulmonary infarction.<sup>33</sup> Osler noted in 1899 that “It is not infrequent to find total obstruction of a large branch of a pulmonary artery

without hemorrhage.”<sup>40</sup> In 1909, he noted: “In cases where small blood vessels are obstructed, infarction results”.<sup>41</sup>

### *What Are the Clinical Signs of Pulmonary Infarction?*

The pathologic findings in patients with pulmonary infarction were well-described by Osler in 1899,<sup>40</sup> but the associated clinical findings were not well-described. Osler stated the following: “The symptoms (of pulmonary infarction) are by no means definite, but it may be suspected in chronic heart disease when hemoptysis occurs, particularly in mitral stenosis.” He also stated that with large infarcts there may be signs of consolidation.<sup>40</sup>

Steell<sup>41</sup> described the clinical findings of pulmonary infarction in great detail in 1906. He described hemoptysis, pleuritic chest pain, a pleural friction rub, and signs of consolidation and small pleural effusions. He distinguished these clinical findings from those of massive, central embolism in which the patient “is seized unexpectedly with intensive dyspnea and intrathoracic distress.”

### *Massive Pulmonary Embolism/Acute Cor Pulmonale*

Virchow<sup>1</sup> clearly distinguished massive pulmonary embolism from submassive pulmonary embolism. He noted the following: “Into the pulmonary artery the introduced fragments of thrombus of course penetrate to different depths according to their size. . . . In the case of very large fragments even the principal trunks of the pulmonary artery are blocked up and instantaneous asphyxia ensues.”

Osler’s discussion<sup>40</sup> of pulmonary embolism in 1899 described pulmonary infarction in detail but did not mention massive pulmonary embolism.

Steell<sup>41</sup> in 1906 described pulmonary infarction and also described pulmonary embolism presenting as “unexpected intensive dyspnea and intrathoracic distress of indefinite character.” He noted that “such dyspnea, if survived, is apt to subside.”

MacKenzie<sup>42</sup> in 1908 described pulmonary infarction and noted that, in other patients, pulmonary embolism causes “intensive dyspnea with gradual loss of consciousness.” He noted that these patients may survive.

The term *acute cor pulmonale* was introduced by McGinn and White<sup>43</sup> in 1935. They described nine cases of massive pulmonary embolism in which the diagnosis was confirmed postmortem or by pulmonary embolectomy. They described shock and collapse accompanied by dilatation of the pulmonary artery and the right heart chambers. Engorgement of the neck veins was noted in each case and was seen

as “direct evidence of increased venous pressure resulting from failure of the right side of the heart.” They used the term *acute cor pulmonale* to distinguish it from chronic cor pulmonale due to progressive enlargement of the right side of the heart secondary to various pulmonary diseases. Their observation that shock and cardiovascular collapse due to pulmonary embolism were due to a massive, central embolism was consistent with the early experimental studies of Haggart and Walker,<sup>44</sup> who studied the physiology of pulmonary embolism by clamping the pulmonary arteries of cats. They reported that clamping the main left pulmonary artery causes an increase in pulmonary artery pressure but no change in systemic BP. Systemic pressure remained normal until they had occluded 52 to 66% of the pulmonary circulation.<sup>44</sup>

In seven of the nine cases reported by McGinn and White,<sup>43</sup> ECGs were performed. Five patients underwent ECGs within 24 h of the acute attack. The authors reported that they were “notable because of their similarities.” They described the pattern that we currently term S<sub>1</sub>Q<sub>3</sub>T<sub>3</sub>. Repeat ECGs in two patients that were made after recovery showed a complete disappearance of the ECG changes.

The hemodynamic and angiographic correlates of acute cor pulmonale were studied in the Dexter Laboratory over a 10-year period. Nearly all patients suspected of having acute pulmonary embolism underwent right heart catheterization and pulmonary angiography.<sup>45</sup> In patients without prior heart disease, it was noted that, even in the face of massive pulmonary embolism, their pulmonary artery systolic pressure rarely exceeded 50 to 60 mm Hg. In patients with massive pulmonary embolism as documented by pulmonary angiography, right atrial pressure was increased to 10 to 22 mm Hg. Cardiac index was normal or above normal, except in patients with acute cor pulmonale (*ie*, those patients had elevated right atrial pressure) [Fig 2]. Hypotension was present in patients with reduced cardiac index and right heart failure (*ie*, elevated mean right atrial pressure). These hemodynamic and angiographic findings<sup>45</sup> are consistent with the clinical observations of McGinn and White.<sup>43</sup> When massive pulmonary embolism occurs in a patient without prior heart or lung disease, the right ventricle can generate pressure up to 50 to 60 mm Hg. At that point, the right ventricle dilates, and the right ventricular end-diastolic pressure (and mean right atrial pressure) increase. Right ventricular stroke volume decreases, cardiac output decreases, and hypotension occurs, as is shown in Table 5. Follow-up studies in these patients with acute pulmonary embolism demon-

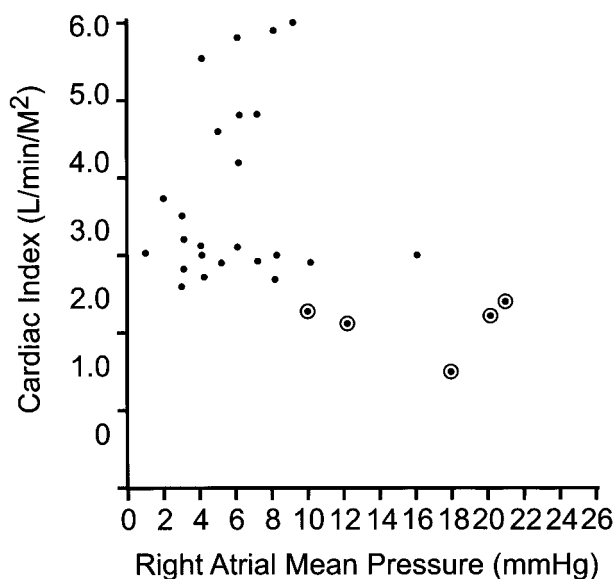


FIGURE 2. Hemodynamic findings in 29 patients with angiographically documented acute pulmonary embolism who did not have prior heart or lung disease. Note that each of the five patients with hypotension (circled dots) had a cardiac index of  $< 2.0$  L/min/m<sup>2</sup> and evidence of right heart failure (mean right atrial pressure,  $\geq 10$  mm Hg). Reprinted with permission by Dalen et al.<sup>45</sup>

stated that as the degree of embolic obstruction decreases, right heart pressures return to near-normal levels.<sup>45</sup>

#### Acute Unexplained Dyspnea

The syndrome of pulmonary infarction is seen in approximately 50 to 60% of patients with documented pulmonary embolism, and the syndrome of acute cor pulmonale is present in an additional 10 to 15% of patients.<sup>33</sup>

The recognition of pulmonary embolism in the absence of pulmonary infarction or acute cor pulmonale represents a significant challenge. We have used the term *acute unexplained dyspnea*<sup>33</sup> because these

patients usually present with acute dyspnea. Pulmonary angiography demonstrates submassive pulmonary embolism that is insufficient to cause acute cor pulmonale but is sufficient to cause dyspnea.

Physical examination demonstrates tachypnea and usually tachycardia. The only other positive physical findings may be signs of DVT, as is the case in other patients with pulmonary embolism. The chest radiograph and ECG findings are normal.

The principal initial differential diagnosis includes congestive heart failure and pneumonia, which are excluded by further history, physical examination, and the results of a chest radiograph. Given the lack of findings other than acute dyspnea and tachypnea, hyperventilation may be suspected. The key laboratory test in this setting is arterial blood gas analysis. The findings of hypoxemia and hypocapnia quickly distinguish pulmonary embolism from the hyperventilation syndrome.

#### DIAGNOSTIC TESTS FOR PULMONARY EMBOLISM

As noted, the accuracy of the diagnosis of pulmonary embolism based on history and physical examination alone is notoriously low. However, signs and symptoms alert the clinician to suspect pulmonary embolism, and, once pulmonary embolism is suspected, there are a variety of diagnostic tests available to help clarify the diagnosis, as shown in Table 6. The sensitivity and specificity of these tests are quite variable, as will be discussed.

#### Chest Radiograph

Although the majority of patients with pulmonary embolism have an abnormal findings on chest radiographs, the most frequent abnormalities (*ie*, pleural effusion, pleural-based opacity, elevated hemidiaphragm, atelectasis, and consolidation) are nonspecific.<sup>46</sup>

In a landmark article on the roentgen diagnosis of lung embolism, Westermark<sup>47</sup> stated the following: “The roentgenologic diagnosis of embolism of the pulmonary artery is very difficult particularly in cases without infarction.” Westermark was perhaps the first to differentiate the radiograph findings in patients with infarctions from those without. He reported the radiograph findings in 26 patients with autopsy-proven pulmonary embolism. Ten of the 26 patients had pulmonary infarction. The predominant radiograph finding in those with infarction was the presence of a “wedge-shaped shadow.” Infarctions had been described earlier by Kohlman<sup>48</sup> as a “triangular or rounded massive shadow.”

Westermark<sup>47</sup> pointed out that most patients with pulmonary embolism do not have a pulmonary in-

Table 5—Acute Cor Pulmonale\*

Massive acute PE
↓
Acute right ventricular failure
↓
Stroke volume decrease
↓
Cardiac output decrease
↓
Hypotension
↙ ↓ ↘
Syncope, cardiac arrest, or recovery

\* ↓ = Leads to. See Table 3 for abbreviations not used in the text.

**Table 6—Diagnostic Tests for PE**

Tests	Initial Report	Confirming Report*
Chest radiograph	Kohlman, <sup>48</sup> 1924 Westermarck, <sup>47</sup> 1938	Hampton and Castleman, <sup>38</sup> 1940
ECG	McGinn and White, <sup>43</sup> 1935 Durant et al, <sup>50</sup> 1939	Szucs et al, <sup>51</sup> 1971
Arterial blood gases	Robin et al, <sup>53</sup> 1960	Szucs et al, <sup>51</sup> 1971
Pulmonary angiography	Robb and Steinberg, <sup>57</sup> 1939 Aitchison and McKay, <sup>60</sup> 1956	Williams et al, <sup>61</sup> 1963
Lung scans	Wagner et al, <sup>65</sup> 1964	Fred et al, <sup>67</sup> 1966
FSP/D-dimer	Wilson et al, <sup>69</sup> 1971	Rickman et al, <sup>70</sup> 1973
Echocardiography	Steckley et al, <sup>78</sup> 1978	Kasper et al, <sup>79</sup> 1980
Chest CT scan	Sinner, <sup>92</sup> 1978	Remy-Jardin et al, <sup>93</sup> 1992

\*Confirmed by pulmonary angiography or postmortem examination.

farction, especially patients without “manifest stasis of the pulmonary veins” or defects of the mitral valve.

In patients without infarction, Westermarck noted “anemia” (oligemia) of the lung area corresponding to the embolized arterial branch. He noted that “in the case of larger emboli, a whole lobe or an entire lung may be anemic.” These areas of decreased pulmonary vascularity have been termed *Westermarck sign*. In a series of 383 patients with angiographically proven pulmonary embolism reported by Stein et al,<sup>46</sup> only 6% had Westermarck sign. The contribution of Westermarck was his observation that the wedge-shaped shadow only occurred in patients with pulmonary embolism complicated by infarction.

The definitive study of radiograph findings in patients with pulmonary infarction was presented in the landmark article by Hampton and Castleman<sup>38</sup> in 1940. They performed postmortem radiographs and compared the findings with those obtained during postmortem examinations. They found a nearly 1:1 relationship between the findings of the pathologist and those of the radiograph. The radiographic appearance of an infarct is a shadow or density corresponding to the lung segment involved. The shadow or density is always in contact with one or more pleural surfaces. The cardiac margin of the consolidation was noted to be sharp in outline and convex or hump-shaped. At this early stage, the infarction is hemorrhagic or incomplete. In patients without heart disease, the incomplete infarction may heal without scarring. In patients with pulmonary congestion, the infarction may pass through a healing phase, finally ending in the formation of a scar. As the healing occurs, the infarction may produce a sharp, dense line, a linear shadow that by radiograph may be confused with plate-like atelectasis.<sup>49</sup>

These landmark studies by Westermarck<sup>47</sup> and Hampton and Castleman<sup>38</sup> remain our best de-

scriptions of the radiograph findings in pulmonary embolism patients with and without pulmonary infarctions.

### ECG

The ECG finding is abnormal in the majority of patients with pulmonary embolism. In two series of patients with pulmonary embolism who did not have prior cardiac or pulmonary disease, 70% had abnormal ECG findings.<sup>46</sup> However, in the vast majority of cases the observed ECG abnormalities were nonspecific.

The most specific ECG abnormality was reported in the landmark article by McGinn and White in 1935.<sup>43</sup> They examined the ECGs of seven patients with massive pulmonary embolism. In five cases, the ECG was taken within 24 h of the acute attack. In each case, there was a prominent S wave in lead I, and a Q wave and negative T wave in lead III. This ECG finding, now termed the  $S_1Q_3T_3$  pattern, was reported to be due to acute cor pulmonale secondary to acute massive pulmonary embolism. Follow-up ECGs taken in two patients after they had recovered had returned to normal.

A second specific ECG finding in patients with massive pulmonary embolism was reported by Durant et al in 1939.<sup>50</sup> They noted right bundle branch block in two patients with pulmonary embolisms that were complicated by shock. In both cases, the ECGs reverted to normal within 24 h.

Subsequent studies have shown that the appearance of a new  $S_1Q_3T_3$  or a new right bundle-branch block is quite specific for acute pulmonary embolism. The incidence of these two ECG findings in a given series of patients with pulmonary embolism will depend on the incidence of massive pulmonary embolism in the series. In a series of 47 patients with angiographically documented acute pulmonary embolism reported by the Dexter Laboratory,<sup>51</sup> 9 pa-

tients (19%) had the  $S_1Q_3T_3$  pattern or new complete or incomplete right bundle branch block.

In a study from the Dexter Laboratory,<sup>52</sup> the clinical findings in 17 patients with syncope due to acute massive pulmonary embolism were compared to 115 patients with acute pulmonary embolism without syncope. Angiograms demonstrated obstruction of > 50% of the pulmonary circulation in 15 of the 17 patients with syncope. Sixteen of these 17 patients had acute cor pulmonale (mean right atrial pressure, > 8 mm Hg), and 13 patients were in shock. Ten of these patients (60%) had a new  $S_1Q_3T_3$  or new incomplete right bundle branch block. Only 12% of the patients without syncope had these ECG findings.<sup>52</sup>

### Arterial Blood Gases

Cyanosis has long been associated with massive pulmonary embolism<sup>43</sup>; however, it remained for Robin et al<sup>53</sup> in a 1960 report to measure arterial saturation in patients with a clinical diagnosis of pulmonary embolism. Eleven patients with signs and symptoms suggesting massive pulmonary embolism were studied, and the diagnosis of massive pulmonary embolism was confirmed postmortem in 6 of the 11 patients. Arterial saturation (room air) varied from 34 to 90%. Tachypnea was present in most patients, with the respiratory rate varying from 16 to 59 breaths/min. Ten of the 11 patients had a respiratory rate of > 20 breaths/min.

In a small series of five patients with angiographically documented pulmonary embolism, Sasahara et al<sup>54</sup> in 1964 reported that four of five patients had a  $PaO_2$  level (while breathing room air) of < 80 mm Hg. The one patient with a  $PaO_2$  level of > 80 mm Hg presented with symptoms of pulmonary infarction. Pulmonary angiography in this patient demonstrated submassive pulmonary embolism limited to the right lower lobe.<sup>54</sup>

A study from the Dexter Laboratory in 1971<sup>51</sup> was the first to report the results of arterial blood gas analysis in a large series of patients with acute pulmonary embolism documented by selective pulmonary angiography. Arterial blood gases (while breathing room air) were measured in 36 of 50 patients with documented acute pulmonary embolism. All 36 had a  $PaO_2$  levels of < 80 mm Hg, 82% had  $PaCO_2$  levels of < 40 mm Hg, and 92% had a pH of > 7.40. The authors concluded that "a normal arterial  $PaO_2$  or normal lung scan essentially excludes the diagnosis of acute pulmonary embolism." Subsequent studies proved them to be half right. A normal lung scan finding essentially excludes the diagnosis of acute pulmonary embolism,<sup>23</sup> but a normal  $PaO_2$  level (*ie*, > 80 mm Hg) does not.

Overton and Bocka<sup>55</sup> in 1988 reported that 3 of 64 patients with angiographically documented pulmonary embolism had normal  $PaO_2$  levels (87, 90, and 91 mm Hg). It is of note that none of these patients presented with signs or symptoms of massive pulmonary embolism and that none were hypotensive. Two of the three presented with symptoms consistent with pulmonary infarction. Angiograms confirmed nonmassive pulmonary embolism in all three cases.

More compelling evidence that a normal  $PaO_2$  level cannot be used to exclude pulmonary embolism came from an analysis of data from the PIOPED study.<sup>56</sup> Of 280 patients with acute pulmonary embolism, 25% of patients with no prior cardiopulmonary disease had a  $PaO_2$  level of > 80 mm Hg, and 15% of patients with pulmonary embolism with prior cardiopulmonary disease had a  $PaO_2$  level of > 80 mm Hg. The calculation of the alveolar-arterial oxygen pressure difference ( $P[A-a]O_2$ ) demonstrated a normal  $P(A-a)O_2$  in 11 to 14% of these 280 patients with documented acute pulmonary embolism.

The arterial  $PaO_2$  is most likely to be abnormal in patients with massive pulmonary embolism and is more likely to be normal in patients with submassive pulmonary embolism. Patients who present with the signs and symptoms of pulmonary infarction are the most likely to present with submassive pulmonary embolism and a normal arterial  $PaO_2$  level.

In the PIOPED study,<sup>56</sup> there was a linear correlation of the  $P(A-a)O_2$  with the severity of pulmonary embolism, as assessed by pulmonary artery mean pressure, and with the number of mismatched perfusion defects. The results of a clinical study from the Dexter Laboratory<sup>62</sup> are consistent with the PIOPED data.<sup>52</sup> In a series of 132 patients with angiographically documented acute pulmonary embolism, 17 (13%) presented with syncope secondary to massive pulmonary embolism. Seventy-six percent had hypotension, and 24% had cardiac arrest. Angiograms revealed > 50% obstruction in 82% of patients. Fourteen of these 17 patients (83%) had a  $PaO_2$  of < 60 mm Hg. Of 115 patients without syncope, only 31% had a  $PaO_2$  level of < 60 mm Hg.<sup>52</sup>

Given these observations, what is the role of arterial blood gas analysis in patients with suspected pulmonary embolism? A normal  $PaO_2$  certainly does not rule out pulmonary embolism. However, a normal  $PaO_2$  in a patient with hypotension or signs of acute cor pulmonale makes it very unlikely that the signs and symptoms are due to pulmonary embolism. In patients without acute cor pulmonale or pulmonary infarction who present with acute dyspnea, the arterial  $PaO_2$  can be helpful in distinguishing between acute pulmonary embolism and the hyperven-

tilation syndrome. In patients with documented pulmonary embolism, PaO<sub>2</sub> helps to indicate its hemodynamic severity.<sup>56</sup>

### Pulmonary Angiography

The development of pulmonary angiography greatly facilitated our understanding of pulmonary embolism. Prior to the advent of pulmonary angiography, the diagnosis of pulmonary embolism during life could be made only with certainty during a pulmonary embolectomy.

The first successful angiographic visualization of the pulmonary circulation in humans was reported by Robb and Steinberg<sup>57</sup> in 1939. They injected diodrast through large-bore needles into arm veins. Chest radiographs taken at varying times from the time of the injection allowed clear visualization of the right heart chambers, the pulmonary arterial circulation, and the left heart. Their “contrast roentgenograms” demonstrated normal pulmonary circulation, and altered circulation in patients with tuberculosis and chronic lung disease. They did not study patients with suspected pulmonary embolism.

Jesser and de Takats<sup>58</sup> used the Robb-Steinberg technique to perform pulmonary angiograms in dogs. They injected IV a mixture containing barium sulfate to cause a pulmonary embolism. Pulmonary angiographs taken before and after embolization demonstrated obstructed pulmonary arteries and “mural defects.” They reported that experimental pulmonary embolism causes sudden dilation of the right heart.

Lochhead et al<sup>59</sup> induced autologous clots in the jugular veins of dogs and then released them to cause a pulmonary embolism. They used a rapid film changer to perform pulmonary angiography (two exposures per second). They noted embolic obstruction of the pulmonary arteries, but they reported that in most cases the pulmonary artery occlusions were not complete, blood being able to pass the clot, which was recognized as a “filling defect.”

The first report of the angiographic diagnosis of probable pulmonary embolism in humans was made by Aitchison and McKay in 1956.<sup>60</sup> They reported the workup of a 57-year-old man who had complained of epigastric pain and had no respiratory complaints. His chest radiograph demonstrated a translucent area in the right upper lung (*ie*, Westermark sign). Bronchography confirmed a normal bronchus to the right upper lobe. On the basis of these findings, the authors performed selective pulmonary angiography with injection into the right main branch of the pulmonary artery. The resultant angiogram documented absent perfusion of the right upper lobe, although an obstructed artery (cutoff) or

filling defect was not noted. They attributed this finding to a respiratory illness characterized by hemoptysis and chest pain in the prior year.

The landmark study of pulmonary angiography to diagnose pulmonary embolism in man was that of Williams et al<sup>61</sup> in 1963. They reported a study of 50 patients who were suspected of acute or recurrent pulmonary embolism. They utilized the Robb-Steinberg technique of IV injection of contrast material and used a rapid film changer. They avoided selective pulmonary angiography because of the fear of dislodging emboli within the right heart or main branches of the pulmonary artery. They recognized pulmonary embolism as a blunt obstruction of opacified arteries (*ie*, cutoffs) or as a central defect with circumferential opacification around the embolus (*ie*, filling defects). These angiographic abnormalities were noted in 73% of 27 patients who were suspected of acute pulmonary embolism.

Wilhelmsen et al<sup>62</sup> and Sasahara et al<sup>54</sup> used selective pulmonary angiography by injecting contrast material into the main pulmonary artery or the right ventricular overflow tract to study pulmonary embolism. The selective technique soon became the technique of choice, allowing better visualization of the distal pulmonary circulation (Table 7).

The angiographic criteria for acute pulmonary embolism were reported in a study from the Dexter Laboratory.<sup>63</sup> The results of selective pulmonary angiography in 71 patients with or without suspected pulmonary embolism were evaluated. Filling defects, cutoffs, pruning (*ie*, a well-visualized artery with a paucity of small branches in comparison to similar sized arteries in other parts of the lung) were seen only in patients with clinical evidence of pulmonary embolism. Other abnormalities, including oligemia, asymmetrical filling, prolongation of the arterial phase, and bilateral lower lobe delay, were seen in patents with pulmonary embolism but were seen also in those with chronic lung disease and congestive heart failure.<sup>63</sup>

By the end of the 1960s, selective pulmonary

**Table 7—Early Reports of Selective Pulmonary Angiography To Detect Pulmonary Embolism**

Report	Year	Cases, No.
Aitchison and McKay <sup>60</sup>	1956	1
Wilhelmsen et al <sup>62</sup>	1963	2
Sasahara et al <sup>54</sup>	1964	4
Fred et al <sup>67</sup>	1966	73
Ormand et al <sup>64</sup>	1966	35*
Stein et al <sup>63</sup>	1967	71
Dalen et al <sup>30</sup>	1971	245

\*Some cases were selective, some by IV injection.

angiography was widely accepted as the most accurate technique for the diagnosis of acute pulmonary embolism. The safety of this technique was reported by the Dexter Laboratory in 1971.<sup>30</sup> The results of selective angiography performed in 367 patients suspected of acute pulmonary embolism from 1964 to 1970 were reported in 1971. There were a total of 13 complications (4%) related to cardiac catheterization or angiography. The only death in the 367 studies occurred in a patient with primary pulmonary hypertension complicated by acute pulmonary embolism. She developed electromechanical dissociation with cardiogenic shock immediately after the injection of 40 mL contrast material into the main pulmonary artery.<sup>30</sup>

The establishment of selective pulmonary angiography as the “gold standard” for the diagnosis of pulmonary embolism allowed the validation of other techniques, such as  $\dot{V}/\dot{Q}$  scanning. Furthermore, its establishment allowed for a re-evaluation of the signs and symptoms of pulmonary embolism.<sup>51</sup> Follow-up angiography led to a better understanding of the resolution rate and natural history of pulmonary embolism.<sup>45</sup>

### Lung Scans

Perfusion lung scans were introduced by Wagner and colleagues<sup>65</sup> at Johns Hopkins in 1964, just after the introduction of pulmonary angiography. Wagner et al<sup>65</sup> demonstrated in their landmark article that radioiodinated human serum albumin (<sup>131</sup>I-labeled macroaggregated albumin), when injected IV, accumulated to a high degree in the lungs. They then caused pulmonary embolism in dogs by injecting latex balloons filled with radiopaque contrast medium into an external jugular vein. In each case, the site of vascular occlusion was determined correctly by scanning the lungs as confirmed by the radiographic location of the opaque embolus.

After determining the safety of the technique in dogs and humans, they performed lung scans in 100 patients. Pulmonary embolism was diagnosed by lung scan in 14 patients who had perfusion defects (*ie*, avascular areas) with confirmation by selective pulmonary angiography, autopsy, or embolectomy. They described the avascular areas as crescent-shaped defects occurring particularly at the lateral borders of the lungs.

They emphasized the importance of correlating the scan findings with the plain chest radiograph. They noted that all lesions detected by plain chest radiograph, whether from infarction, pneumonia, atelectasis, abscess, or tumor, would result in decreased radioactivity by lung scan. Lopez-Majano and his colleagues<sup>66</sup> at Johns Hopkins performed

lung scans in 60 patients with emphysema and found that 95% of them had regions of decreased pulmonary artery blood flow. Thus, the lack of specificity of the perfusion lung scan was apparent at the onset. The sensitivity of the lung scan would await subsequent studies.

The sensitivity of lung scans was assessed by Fred et al<sup>67</sup> in 1966. They reported the results of lung scans and selective pulmonary angiography in 73 patients suspected of having acute pulmonary embolism. Of 27 patients with angiographically documented pulmonary embolism, the lung scan was abnormal in 26 patients. There was one false-negative lung scan finding in a patient with complete obstruction of the distal end of a segmental artery.

Another study<sup>30</sup> of the sensitivity and specificity of perfusion scans was reported by the Dexter Laboratory in 1971. Over a 5-year period (1964 to 1969), selective pulmonary angiography was performed in 227 patients with suspected acute pulmonary embolism. Of 50 patients with unequivocal angiographic evidence of acute pulmonary embolism, 24 underwent perfusion scans, all results of which were abnormal. Of 85 patients suspected of having pulmonary embolism who had normal pulmonary angiogram findings, 44 underwent perfusion scans, with abnormal findings in 34. The investigators concluded that a normal lung scan finding essentially excludes the presence of acute pulmonary embolism. An abnormal perfusion scan finding is not specific for pulmonary embolism.

Wagner and colleagues<sup>65</sup> reported the use of ventilation lung scans utilizing radioactive xenon in 1968. They reported that the finding of normal ventilation in segments that were abnormal by perfusion (<sup>131</sup>I-labeled macroaggregated albumin) increases the probability of pulmonary embolism, thereby increasing the specificity of the lung scan.

The most comprehensive assessment of the sensitivity and specificity of  $\dot{V}/\dot{Q}$  scans for the diagnosis of acute pulmonary embolism was reported in the landmark PIOPED study.<sup>23</sup> Seven hundred fifty-five patients underwent  $\dot{V}/\dot{Q}$  scans and selective pulmonary angiography within 24 h of the occurrence of symptoms that suggested pulmonary embolism. Thirty-three percent (251) of the patients had angiographic evidence of pulmonary embolism. Almost all patients with pulmonary embolism (98%) had abnormal  $\dot{V}/\dot{Q}$  scan findings. Five patients (2%) had “near-normal” or normal scan findings. The very high sensitivity of  $\dot{V}/\dot{Q}$  scans was confirmed.

High-probability scans were defined as two or more moderate or large segmental perfusion defects without corresponding ventilation or roentgenographic abnormalities. Pulmonary embolism was documented by angiography in 88%. However, only

41% of the patients with pulmonary embolism had a high-probability scan. The majority of patients with pulmonary embolism (57%) had an intermediate-probability or low-probability scan.

The results of the PIOPED study indicate that a high-probability scan is nearly specific (88%) for acute pulmonary embolism. A normal scan finding essentially excludes significant pulmonary embolism. However, the majority of patients suspected of having acute pulmonary embolism will have an intermediate-probability or low-probability scan in which the specificity for pulmonary embolism is 30% and 14%, respectively. In the circumstance of indeterminate or low-probability scans, the diagnosis of acute pulmonary embolism can be neither confirmed nor excluded.

#### *Fibrin Split Products/D-dimer*

The presence of elevated levels of fibrin split products (FSPs) in patients with pulmonary embolism was reported by Wilson et al in 1971.<sup>69</sup> These findings were confirmed by angiographic studies in the Dexter Laboratory in 1973.<sup>70</sup> Although these early studies demonstrated significant sensitivity (but minimal specificity) for pulmonary embolism, the measurement of FSPs to diagnose or exclude pulmonary embolism did not achieve clinical acceptance.

The early tests for FSPs were sensitive to fibrinogen and its degradation products, and therefore were not specific for fibrin derivatives.<sup>71</sup> Newer tests involving an immunoassay using monoclonal antibodies to specifically measure cross-linked fibrin derivatives in plasma renewed interest in this diagnostic test.<sup>71,72</sup> These tests are specific for d-dimer and other larger cross-linked fibrin derivatives.<sup>73</sup>

The following two types of tests have been developed: the enzyme-linked immunosorbent (ELISA) test; and the rapid latex agglutination test. The advantage of the latex test is that it can be performed rapidly, whereas the standard ELISA test for d-dimer requires several hours.

Measurement of d-dimer by these two techniques has clearly established that the sensitivity of the ELISA test greatly exceeds that of the rapid latex test. In an early study comparing these two tests, in a group of 62 patients undergoing venography for DVT, the sensitivity of the ELISA was 100% compared to 73% for the latex test.<sup>73</sup> Bounameaux et al<sup>74</sup> reported similar results as follows: ELISA sensitivity, 100%; and sensitivity for the two latex tests, 60% and 67%. The negative predictive value of a normal d-dimer test result is greater in patients with a low clinical probability of VTE.<sup>31,32</sup>

The sensitivity of a number of rapid ELISA tests has been investigated. The sensitivity of these newer

rapid tests for VTE varies from 90 to 95%.<sup>75</sup> However, in one study<sup>76</sup> of 198 emergency department patients, the sensitivity for VTE was only 65%. The verification of a sensitivity near 100% of a rapid ELISA test will be of immense value in avoiding the further workup of patients in whom the clinical suspicion of VTE is low.

#### *Echocardiography*

Since the report by Covarrubias et al<sup>77</sup> in 1977 of the detection of a thrombus adjacent to the tricuspid valve by M-mode echocardiography in a patient who died of documented massive pulmonary embolism 48 h later, echocardiography has become one of the tests used to evaluate patients with suspected pulmonary embolism.

The first report of the echocardiographic findings in a patient with acute pulmonary embolism documented by selective pulmonary angiography was by Steckley et al<sup>78</sup> in 1978. They reported a patient who had undergone echocardiography before and after an episode of acute pulmonary embolism that was documented by pulmonary angiography. They noted the development of right ventricular dilatation and paradoxical septal motion after the episode of acute pulmonary embolism. A follow-up echocardiogram after treatment showed a complete return to normal.<sup>78</sup>

Kasper et al<sup>79</sup> in 1980 reported findings by M-mode echocardiography in 18 patients with angiographically documented pulmonary embolism. None of the patients had known prior cardiopulmonary disease. The investigators reported dilatation of the right pulmonary artery that correlated with increased mean pulmonary artery pressure. The right ventricle was dilated in 13 of 16 patients, while the left ventricular dimension was decreased in 10 of 15 patients. The ratio of right ventricular end-diastolic dimension/left ventricular end-diastolic dimension was above normal in 14 of 15 patients. The right ventricle/left ventricle ratio correlated well with the angiographic severity of embolic obstruction. In a later report by Miller et al,<sup>80</sup> the extent of right ventricular end-systolic area enlargement and decreased right ventricular fractional change did not correlate with the degree of pulmonary vascular obstruction as assessed by perfusion lung scans in 64 patients with acute pulmonary embolism who had no prior cardiopulmonary disorders. Other studies<sup>81,82</sup> have reported the detection of thrombus within the right pulmonary artery using two-dimensional echocardiography with a suprasternal approach.

In 1986, Kasper et al<sup>83</sup> reported the findings by M-mode or two-dimensional echocardiography in 105 patients with acute pulmonary embolism documented by pulmonary angiography, V/Q scan, or

postmortem examination. Their findings are shown in Table 8. Dilatation of the right pulmonary artery and dilatation of the right ventricle were the most frequent findings but are not specific for acute pulmonary embolism. Visualization of a clot in the pulmonary artery would appear to be highly specific for pulmonary embolism. Of note is the fact that 19% of these patients with documented pulmonary embolism had normal echocardiogram findings. Kasper et al<sup>83</sup> were the first to report that a normal echocardiogram finding does not rule out acute pulmonary embolism.

Come et al<sup>84</sup> reported that serial echocardiograms can be used to assess the hemodynamic response to the treatment of pulmonary embolism. They studied eight patients before and after a 6-h infusion of recombinant human tissue plasminogen activator. The resolution of embolic obstruction was assessed by serial pulmonary angiography, lung scan, and the measurement of right-sided pressures. As embolic obstruction began to resolve, they noted a decrease in the right ventricular diameter, an increase in the left ventricular diameter, an improvement of right ventricular hypokinesis, and a decrease in tricuspid regurgitation. Subsequent studies<sup>85,86</sup> have used serial echocardiography to assess the response to treatment in patients with acute pulmonary embolism.

In a review of the echocardiography findings in patients with acute pulmonary embolism, Come<sup>85</sup> confirmed the findings of echocardiography that had been reported by Kasper et al<sup>83</sup> (Table 8). In addition to these abnormalities, Come noted that right ventricular hypokinesis is an important finding in patients with pulmonary embolism and that the flow velocities in tricuspid and pulmonary regurgitant jets can be used to reliably estimate pulmonary artery systolic and diastolic pressures.<sup>85</sup>

Ribeiro et al<sup>87</sup> reported the results of Doppler echocardiography in 126 patients with acute pulmonary embolism documented by  $\dot{V}/\dot{Q}$  scan or angiography. Nineteen percent of these patients with documented pulmonary embolism had a normal finding

on their Doppler echocardiography study, as had been reported previously by Kasper et al.<sup>83</sup> Ribeiro et al<sup>87</sup> found that 44% of patients had no or slight right ventricular hypokinesis, while 56% had moderate-to-severe right ventricular hypokinesis. This compares to an incidence of right ventricular hypokinesis of 40% in hemodynamically stable patients in the International Cooperative Pulmonary Embolism Registry as reported by Goldhaber.<sup>88</sup> Ribeiro et al noted that the following two factors were associated with increased mortality in their 126 patients: the presence of cancer; and the presence of right ventricular hypokinesis. In patients without cancer, the 1-year pulmonary embolism mortality rate was 0% in those without right ventricular hypokinesis, compared to 7.7% in those with right ventricular hypokinesis.<sup>87</sup> Kasper et al<sup>89</sup> have reported that right ventricular hypokinesis is associated with increased mortality in patients with pulmonary embolism.

In a unique study, Krivec and coworkers<sup>90</sup> utilized bedside transesophageal echocardiography (TEE) to assess 24 critically ill patients with unexplained shock and distended jugular veins. They found that 17 of the 24 patients had right ventricular dilatation with global hypokinesis. TEE examination detected pulmonary emboli in the central circulation (main pulmonary artery, right pulmonary artery, or left pulmonary artery) in 12 of these 17 patients and reduced right pulmonary artery flow was demonstrated in 1 additional patient. Massive pulmonary embolism was documented by lung scan or postmortem examination in 12 of these 13 patients (90%). In a larger series of patients who had severe pulmonary embolism as assessed by echocardiographic evidence of right heart pressure overload, Wittlich et al<sup>91</sup> demonstrated central pulmonary embolism in the main, right, or left pulmonary artery in 35 patients (58%) using TEE.

Echocardiography, which is noninvasive and can be performed at the bedside of critically ill patients, is valuable in the evaluation of patients suspected of acute pulmonary embolism. A normal echocardiogram finding does not exclude the presence of pulmonary embolism, but a number of findings including right ventricular dilatation, right ventricular hypokinesis, and dilatation of the right pulmonary artery, while not diagnostic, are frequent findings that can lead to further diagnostic evaluations. TEE detection of emboli in the central pulmonary circulation may prove to be highly specific for pulmonary embolism, although the sensitivity of this finding and its validation by pulmonary angiography remain to be determined. The detection of thrombi in the right heart is a clear indication for treatment.

Echocardiographic evaluation of right ventricular size and contractility is useful in determining the hemodynamic severity of the pulmonary embolism.

**Table 8—Echocardiographic Findings in 105 Patients with Acute Pulmonary Embolism\***

Variable	Percent
Dilatation of right pulmonary artery	77
Dilated right ventricle	75
↓ E/F slope of mitral valve	50
↓ Left ventricular dimension	42
Abnormal IV septal motion	40
Embolus in right pulmonary artery	10
Thrombi in right atrium or right ventricle	4
Normal echocardiogram	19

\*Data reproduced with permission of Kasper et al.<sup>83</sup>

Whether right ventricular hypokinesis is a relevant guide to the need for thrombolytic treatment remains controversial, pending further studies.

### *CT Scan of the Chest*

A report by Sinner<sup>92</sup> of the detection of pulmonary infarcts by conventional chest CT scan sparked interest in this noninvasive (or minimally invasive) test in the diagnosis of pulmonary embolism. Interest in this procedure intensified with the introduction of electron beam CT scanning and spiral volumetric CT (SVCT) scanning. These technologic advances permit a more detailed visualization of the pulmonary circulation, which allows the detection of intraluminal filling defects and cutoffs down to the segmental level.

The report of Remy-Jardin et al<sup>93</sup> in 1992 was particularly promising. They reported the results of SVCT scans and selective pulmonary angiography in 42 patients. All 23 patients with normal findings by SVCT had normal pulmonary arteriogram findings (sensitivity, 100%). There was one false-positive SVCT study (specificity, 96%).

These findings led to many other similar studies. Teigen et al<sup>94</sup> reported similar findings using electron beam CT scanning. In their study of 86 patients who underwent CT scans, only 21 had undergone pulmonary angiography. Gurney,<sup>95</sup> in an editorial in 1993, suggested that “chest CT may be an ideal tool to diagnose suspected pulmonary embolism, obviating  $\dot{V}/\dot{Q}$  scanning entirely and markedly reducing the need for pulmonary angiography.”

Goodman et al<sup>96</sup> reported the results of helical CT scans and pulmonary angiography in 20 patients with suspected pulmonary embolism. When emboli in the main, lobar, or segmental pulmonary arteries were analyzed, CT scan sensitivity was 96% and specificity was 92%. However, when subsegmental vessels were included, the sensitivity of the CT scan decreased to 86%, while the specificity remained at 92%. Goodman et al noted that subsegmental emboli are more difficult to diagnose. Only one of four subsegmental emboli identified by angiogram was detected by CT scan. Yan Rossum et al<sup>97</sup> also found CT scanning to be accurate in pulmonary arteries down to the segmental level, but not in the smaller subsegmental branches.

Two reports<sup>98,99</sup> reviewed the sensitivity and specificity of SVCT scanning in the diagnosis of pulmonary embolism. There was considerable overlap in the studies reviewed in these two reports. Combining the two reports, there were 264 patients in whom SVCT scanning (helical CT scanning) was compared to selective pulmonary angiography as the “gold

standard.” The sensitivity of CT scanning in the 264 patients in the combined series was 87%, with a specificity of 91%.

In an editorial by Bates and Ginsberg<sup>100</sup> accompanying the review by Rathbun et al,<sup>98</sup> some of the reasons for less-than-perfect sensitivity and specificity were discussed. Interobserver and intraobserver variability could be factors influencing the interpretation of CT scans (and pulmonary angiograms). Technically inadequate or inconclusive scans occur in 1 to 10% of CT scans. False-positive CT scans may result from the misdiagnosis of hilar lymph nodes, the partial opacification of pulmonary veins, and perivascular edema in patients with congestive heart failure.<sup>101</sup>

One factor leading to false-negative CT scan findings is a lack of sensitivity for emboli in the subsegmental arteries. This becomes relevant when emboli are limited to subsegmental arteries. Fortunately, pulmonary embolism limited to subsegmental arteries is uncommon (PIOPED Study, 6%).<sup>23</sup>

Chest CT scanning offers many advantages in the diagnosis of pulmonary embolism. It directly identifies the pulmonary embolus as an intraluminal filling defect within a pulmonary artery. It is in direct contrast to the detection of pulmonary embolism without pulmonary infarction by plain chest radiograph where the principal evidence of pulmonary embolism is the appearance of an avascular area in the chest radiograph. An advantage of chest CT scans over  $\dot{V}/\dot{Q}$  scans and pulmonary angiography is the ability to identify other conditions that may have symptoms and signs that are suggestive of pulmonary embolism. These conditions include the following: pneumonia; cardiac disease; pulmonary fibrosis; chest trauma; malignancy; pleural disease; and post-operative changes in the lung.<sup>102</sup> However, this may lead to the unnecessary workup of benign, asymptomatic conditions.

The principal advantage of chest CT scanning in the diagnosis of pulmonary embolism is that it can be performed quickly in critically ill patients. The ideal circumstance for chest CT scanning in diagnosing pulmonary embolism is in critically ill patients with shock and/or signs of acute cor pulmonale. A normal chest CT scan finding in this circumstance essentially rules out central pulmonary embolism as the cause of the patient's signs and symptoms.

A normal finding on a chest CT scan does not exclude pulmonary embolism, especially if the emboli are limited to the subsegmental arteries. The impact of this drawback will have to be determined by follow-up studies of patients suspected of pulmonary embolism, who have had a negative chest CT finding and have not been treated with anticoagulation or inferior vena cava interruption. Until such

studies are reported, I believe that further study of the patient suspected of pulmonary embolism who has a normal finding on chest CT scan is appropriate. This study could include a  $\dot{V}/\dot{Q}$  scan, and/or a noninvasive examination of the legs and measurement of d-dimer. Pulmonary embolism limited to the subsegmental arteries is uncommon, but, given the natural history of VTE in the absence of treatment, it could be followed by recurrent, potentially lethal pulmonary embolism.<sup>18</sup>

**ACKNOWLEDGMENT:** This lecture and article is dedicated to the late Dr. Lewis Dexter (1910 to 1995). In his 34 years on the faculty of Harvard Medical School, he performed fundamental studies in his laboratory at the Peter Bent Brigham Hospital that led to an understanding of congenital and valvular heart disease. He was the first to catheterize the pulmonary artery and to describe pulmonary artery wedge pressure. His special interest in the pulmonary circulation and pulmonary embolism led to many publications on pulmonary embolism by the 60 cardiologists that he trained from 1945 to 1975. Publications on pulmonary embolism from the Dexter Laboratory at the Peter Bent Brigham Hospital are italicized in the "References" section of this article.

## REFERENCES

- Virchow RLK. Cellular pathology. 1859 special ed. London, UK: John Churchill, 1978; 204–207
- Virchow RLK. Cellular pathology as based upon physiological and pathohistology. 7th American ed. Chance F, DeWitt RM, trans. New York, NY: 1860; 236
- Anderson FA, Wheeler HB, Goldberg RJ, et al. Physician practices in the prevention of venous thromboembolism. *Ann Intern Med* 1991; 115:591–595
- Ray JG. Meta-analysis of hyperhomocysteinemia as a risk factor for venous thromboembolic disease. *Arch Intern Med* 1998; 158:2101–2106
- Thomas DP, Roberts HR. Hypercoagulability in venous and arterial thrombosis. *Ann Intern Med* 1997; 126:638–644
- Allaart CF, Poort SR, Rosendaal FR, et al. Increased risk of venous thrombosis in carriers of hereditary protein C deficiency defect. *Lancet* 1993; 341:134–138
- Greengard JS, Eichinger S, Griffin JH, et al. Brief report: variability of thrombosis among homozygous siblings with resistance to activated protein C due to an arg→gln mutation in the gene for factor V. *N Engl J Med* 1994; 331:1559–1562
- Gerhardt A, Scharf RE, Beckmann MW, et al. Prothrombin and factor V mutations in women with a history of thrombosis during pregnancy and the puerperium. *N Engl J Med* 2000; 342:374–380
- Bloemenkamp KWM, Rosendaal FR, Helmerhorst FM, et al. Enhancement by factor V Leiden mutation of risk of deep-vein thrombosis associated with oral contraceptives containing a third-generation progestagen. *Lancet* 1995; 346:1593–1596
- Dahlback B. Inherited thrombophilia: resistance to activated protein C as a pathogenic factor of venous thromboembolism. *Blood* 1995; 85:607–614
- Simioni P, Prandoni P, Lensing AWA, et al. The risk of recurrent venous thromboembolism in patients with an arg→gln mutation in the gene for factor V (factor V Leiden). *N Engl J Med* 1997; 336:399–403
- Margaglione M, Brancaccio V, Giuliani N, et al. Increased risk for venous thrombosis in carriers of the prothrombin g→a gene variant. *Ann Intern Med* 1998; 129:89–93
- Price DT, Ridker PM. Factor V Leiden mutation and the risks for thromboembolic disease: a clinical perspective. *Ann Intern Med* 1997; 127:895–903
- Meijers JCM, Tekelenburg WLH, Bouma BN, et al. High levels of coagulation factor XI as a risk factor for venous thrombosis. *N Engl J Med* 2000; 342:696–701
- Koster T, Blann AD, Briet E, et al. Role of clotting factor VIII in effect of von Willebrand factor on occurrence of deep-vein thrombosis. *Lancet* 1995; 345:152–155
- Kakkar VV, Howe CT, Flanc C, et al. Natural history of postoperative deep-vein thrombosis. *Lancet* 1969; 6:230–232
- Hull RD, Raskob GE, Hirsh J. Prophylaxis of venous thromboembolism: an overview. *Chest* 1986; 89:374S–383S
- Dalen JE, Alpert JS. Natural history of pulmonary embolism. *Prog Cardiovasc Dis* 1975; 17:259–270
- Alpert JS, Smith R, Carlson J, et al. Mortality in patients treated for pulmonary embolism. *JAMA* 1976; 236:1477–1480
- Carson JL, Kelley MA, Duff A, et al. The clinical course of pulmonary embolism. *N Engl J Med* 1992; 326:1240–1245
- Douketis JD, Kearon C, Bates S, et al. Risk of fatal pulmonary embolism in patients with treated venous thromboembolism. *JAMA* 1998; 279:458–462
- Gillum RF. Pulmonary embolism and thrombophlebitis in the United States, 1970–1985. *Am Heart J* 1987; 114:1262–1264
- PIOPED Investigators. Value of the ventilation/perfusion scan in acute pulmonary embolism. *JAMA* 1990; 263:2753–2759
- Stein PD. Pulmonary embolism. Baltimore, MD: Williams and Wilkins, 1996; 34
- Rabinov K, Paulin S. Roentgen diagnosis of venous thrombosis in the leg. *Arch Surg* 1972; 104:134–144
- Hull R, Hirsh J, Sackett DL, et al. Combined use of leg scanning and impedance plethysmography in suspected venous thrombosis. *N Engl J Med* 1977; 296:1497–1500
- Polak JF. Doppler ultrasound of the deep leg veins: a revolution in the diagnosis of deep vein thrombosis and monitoring of thrombolysis. *Chest* 1991; 99:165S–172S
- Tapson VF, Carroll BA, Davidson BL, et al. The diagnostic approach to acute thromboembolism: clinical practice guideline; American Thoracic Society. *Am J Respir Crit Care Med* 1999; 160:1043–1066
- Uhland H, Goldberg LM. Pulmonary embolism: a commonly missed clinical entity. *Dis Chest* 1964; 45:533–536
- Dalen JE, Brooks HL, Johnson LW, et al. Pulmonary angiography in acute pulmonary embolism: indications, techniques, and results in 367 patients. *Am Heart J* 1971; 81:175–185
- Wicki J, Perneger TV, Junod AF, et al. Assessing clinical probability of pulmonary embolism in the emergency ward. *Arch Intern Med* 2001; 161:92–97
- Wells PS, Anderson DR, Stiell RM, et al. Excluding pulmonary embolism at the bedside without diagnostic imaging: management of patients with suspected pulmonary embolism presenting to the emergency department by using a simple clinical model and d-dimer. *Ann Intern Med* 2001; 135:98–107
- Dalen JE, Dexter L. Pulmonary embolism. *JAMA* 1969; 207:1505–1507
- Virchow RLK. *Gesammelte abhandlungen zur wissenschaftlichen medicin*. Frankfurt, Germany: Meidinger sohn u Comp, 1856; 285, 294–296
- Cohnheim J, Litten M. Ueber die folgen der embolie der lungenarterien. *Virchows Arch Pathol Anat* 1875; 115:99
- Karsner HT, Ash JE. Studies in infarctions: I. Experimental bland infarction of the lung. *J Med Res* 1912–1913; 27:205–211

- 37 Chapman DW, Gule LJ, Wheeler PW. Experimental pulmonary infraction: abnormal pulmonary circulation's a prerequisite for pulmonary infraction following an embolus. *Arch Intern Med* 1949; 83:158–163
- 38 Hampton AO, Castleman B. Correlation of postmortem chest teleroentgenograms with autopsy findings. *Am J Roentgenol Radium Ther* 1940; 43:305–326
- 39 Dalen JE, Haffajee CI, Alpert JS, et al. Pulmonary embolism, pulmonary hemorrhage and pulmonary infraction. *N Engl J Med* 1977; 296:1431–1434
- 40 Osler W. *The principles and practice of medicine*. 7th ed. New York, NY: D. Appleton and Company, 1909; 618–619
- 41 Steell G. *Text book on diseases of the heart: Special ed.* Manchester, UK: University Press, 1906; 36–37
- 42 MacKenzie J. *Diseases of the heart*. London, UK: Oxford University Press, 1908; 28–29
- 43 McGinn S, White PD. Acute cor pulmonale resulting from pulmonary embolism. *JAMA* 1935; 104:1473–1480
- 44 Haggart GE, Walker AM. The physiology of pulmonary embolism as disclosed by quantitative occlusion of the pulmonary artery. *Arch Surg* 1923; 6:764–783
- 45 Dalen JE, Banas JS, Brooks HL, et al. Resolution rate of acute pulmonary embolism in man. *N Engl J Med* 1969; 280:1194–1199
- 46 Stein PD, Terrin ML, Hales CA, et al. Clinical, laboratory, roentgenographic, and electrocardiographic findings in patients with acute pulmonary embolism and no pre-existing cardiac or pulmonary disease. *Chest* 1991; 100:598–603
- 47 Westermark N. On the roentgen diagnosis of lung embolism: brief review of the incidence, pathology and clinical symptoms of lung embolism. *Acta Radiol* 1938; 357–372
- 48 Köhlman G. Die klinik und röntgendiagnose des lungeninfarktes. *Fortschr. A.d. Geb. D. Röntgenstrahlen* 1924; 32:1–12
- 49 Fleischner F, Hampton AO, Castleman B. Linear shadows in the lung. *AJR Am J Roentgenol* 1941; 46:610–618
- 50 Durant TM, Ginsburg IW, Roesler H, et al. Transient bundle branch block and other electrocardiographic changes in pulmonary embolism. *Am Heart J* 1939; 17:423–430
- 51 Szucs MM, Brooks HL, Grossman W, et al. Diagnostic sensitivity of laboratory findings in acute pulmonary embolism. *Ann Intern Med*. 1971; 74:161–166
- 52 Thames MD, Alpert JS, Dalen JE. Syncope in patients with pulmonary embolism. *JAMA* 1977; 238:2509–2511
- 53 Robin ED, Forkner CE, Bromberg PA, et al. Alveolar gas exchange in clinical pulmonary embolism. *N Engl J Med* 1960; 262:283–287
- 54 Sasahara AA, Stein M, Simon M, et al. Pulmonary angiography in the diagnosis of thromboembolic disease. *N Engl J Med* 1964; 270:1075–1081
- 55 Overton DT, Bocka JJ. The alveolar-arterial oxygen gradient in patients with documented pulmonary embolism. *Arch Intern Med* 1988; 148:1617–1619
- 56 Stein PD, Goldhaber SZ, Henry JW. Alveolar-arterial oxygen gradient in the assessment of acute pulmonary embolism. *Chest* 1995; 107:139–143
- 57 Robb GP, Steinberg I. Visualization of the chambers of the heart, the pulmonary circulation, and the great blood vessels in man. *Am J Roentgenol Radium Ther* 1939; 41:1–17
- 58 Jesser JH, de Takats G. Visualization of the pulmonary artery during its embolic obstruction. *Arch Surg* 1941; 42:1034–1041
- 59 Lochhead RP, Roberts DJ, Dotter CT. Pulmonary embolism: experimental angiocardigraphic study. *AJR Am J Roentgenol* 1952; 68:627–633
- 60 Aitchison JD, McKay JM. Pulmonary artery occlusion demonstrated by angiography. *Br J Radiol* 1956; 29:398–399
- 61 Williams JR, Wilcox C, Andrews GJ, et al. Angiography in pulmonary embolism. *JAMA* 1963; 184:473–476
- 62 Wilhelmsen L, Selander S, Soderholm B. Recurrent pulmonary embolism. *Medicine* 1963; 42:335–355
- 63 Stein PD, O'Conner JF, Dalen JE, et al. The angiographic diagnosis of acute pulmonary embolism: evaluation of criteria. *Am Heart J* 1967; 73:730–741
- 64 Ormand RS, Gale HH, Drake EH, et al. Pulmonary angiography and pulmonary embolism. *Radiology* 1966; 86:658–662
- 65 Wagner HN, Sabiston DC, McAfee JG, et al. Diagnosis of massive pulmonary embolism in man by radioisotope scanning. *N Engl J Med* 1964; 271:377–384
- 66 Lopez-Majano V, Tow DE, Wagner HN. Regional distribution of pulmonary arterial blood flow in emphysema. *JAMA* 1966; 197:81–84
- 67 Fred HL, Burdine JA, Gonzalez DA, et al. Arteriographic assessment of lung scanning in the diagnosis of pulmonary thromboembolism. *N Engl J Med* 1966; 275:1025–1032
- 68 Wagner HN, Lopez-Majano V, Langan JK, et al. Radioactive xenon in the differential diagnosis of pulmonary embolism. *Radiology* 1968; 91:1168–1174
- 69 Wilson JE, Frenkel EP, Pierce AK, et al. Spontaneous fibrinolysis in pulmonary embolism. *J Clin Invest* 1971; 50:474–480
- 70 Rickman FD, Handin R, Howe JP, et al. Fibrin split products in acute pulmonary embolism. *Ann Intern Med* 1973; 79:664–668
- 71 Rowbothan BJ, Carroll P, Whitaker AN, et al. Measurement of cross-linked fibrin derivatives: use in the diagnosis of venous thrombosis. *Thromb Haemost* 1987; 57:59–61
- 72 Whitaker AN, Elms MJ, Masci PP, et al. Measurement of cross linked fibrin derivatives in plasma: an immunoassay using monoclonal antibodies. *J Clin Pathol* 1984; 37:882–887
- 73 Heaton DC, Billings JD, Hickton CM. Assessment of d-dimer assays for the diagnosis of deep vein thrombosis. *J Lab Clin Med* 1987; 110:588–591
- 74 Bounameaux H, Schneider PA, Reber G, et al. Measurement of plasma d-dimer for diagnosis of deep venous thrombosis. *Am J Clin Pathol* 1989; 91:82–85
- 75 Indik JH, Alpert JS. Detection of pulmonary embolism by d-dimer assay, spiral computed tomography, and magnetic resonance imaging. *Prog Cardiovasc Dis* 2000; 42:261–272
- 76 Farrell S, Hayes T, Shaw M. A negative SimpliRED d-dimer assay result does not exclude the diagnosis of deep vein thrombosis or pulmonary embolus in emergency department patients. *Ann Emerg Med* 2000; 35: 121–125
- 77 Covarrubias EA, Sheikh MU, Fox LM. Brief report: echocardiography and pulmonary embolism. *Ann Intern Med* 1977; 87:720–721
- 78 Steckley R, Smith CW, Robertson RM. Acute right ventricular overload: an echocardiographic clue to pulmonary thromboembolism. *John Hopkins Med J* 1978; 143:122–125
- 79 Kasper W, Meinertz T, Kersting F, et al. Echocardiography in assessing acute pulmonary hypertension due to pulmonary embolism. *Am J Cardiol* 1980; 45:567–572
- 80 Miller RL, Das S, Anandarangam T, et al. Association between right ventricular function and perfusion abnormalities in hemodynamically stable patients with acute pulmonary embolism. *Chest* 1998; 113:665–670
- 81 Kasper W, Treese N, Bechtold H, et al. Diagnosis of acute pulmonary embolism and thrombosis by echocardiography [letter]. *Lancet* 1981; 2:202
- 82 DiCarlo LA, Schiller NB, Herfkens RL, et al. Noninvasive detection of proximal pulmonary artery thrombosis by two-dimensional echocardiography and computerized tomography. *Am Heart J* 1982; 104:879–881
- 83 Kasper W, Meinertz T, Henkel B, et al. Echocardiographic findings in patients with proved pulmonary embolism. *Am*

- Heart J 1986; 112:1284–1290
- 84 Come PC, Kim D, Parker JA, et al. Early reversal of right ventricular dysfunction in patients with acute pulmonary embolism after treatment with intravenous tissue plasminogen activator. *J Am Coll Cardiol* 1987; 10:971–988
- 85 Come PC. Echocardiographic evaluation of pulmonary embolism and its response to therapeutic interventions. *Chest* 1992; 101:151S–162S
- 86 Goldhaber SZ, Haire WD, Feldstein ML, et al. Alteplase vs heparin in acute pulmonary embolism: randomized trial assessing right-ventricular function and pulmonary perfusion. *Lancet* 1993; 341:507–511
- 87 Ribeiro A, Lindmarker P, Juhlin-Dannfelt A, et al. Echocardiography doppler in pulmonary embolism: right ventricular dysfunction as a predictor of mortality rate. *Am Heart J* 1997; 134:479–487
- 88 Goldhaber SZ. Medical progress: pulmonary embolism. *N Engl J Med* 1998; 339:93–104
- 89 Kasper W, Konstantinides S, Geibel A, et al. Prognostic significance of right ventricular afterload stress detected by echocardiography in patients with clinically suspected pulmonary embolism. *Heart* 1997; 77:346–349
- 90 Krivec B, Voga G, Zuran I, et al. Diagnosis and treatment of shock due to massive pulmonary embolism. *Chest* 1997; 112:1310–1316
- 91 Wittlich N, Erbel R, Eichler A, et al. Detection of central pulmonary artery thromboemboli by transesophageal echocardiography in patients with severe pulmonary embolism. *J Am Soc Echocardiogr* 1992; 5:515–524
- 92 Sinner WN. Computed tomographic patterns of pulmonary thromboembolism and infraction. *J Comput Assist Tomogr* 1978; 2:395–399
- 93 Remy-Jardin M, Remy J, Wattine L, et al. Central pulmonary thromboembolism: diagnosis with spiral volumetric CT with the single-breath-hold technique; comparison with pulmonary angiography. *Radiology* 1992; 185:381–387
- 94 Teigen CL, Maus TP, Sheedy PF, et al. Pulmonary embolism: diagnosis with electron-beam CT. *Radiology* 1993; 188:839–845
- 95 Gurney JW. No fooling around: direct visualization of pulmonary embolism. *Radiology* 1993; 188:618–619
- 96 Goodman LR, Curtin JJ, Mewissen MW, et al. Detection of pulmonary embolism in patients with unresolved clinical and scintigraphic diagnosis: helical CT vs angiography. *AJR Am J Roentgenol* 1995; 164:1369–1374
- 97 Yan Rossum AB, Pattynama PM, Tjin ER, et al. Pulmonary embolism: validation of spiral CT angiography in 149 patients. *Radiology* 1996; 201:467–470
- 98 Rathbun SW, Raskob GE, Whitsett TL. Sensitivity and specificity of helical computed tomography in the diagnosis of pulmonary embolism: a systematic review. *Ann Intern Med* 2000; 132:227–232
- 99 Mullins MD, Becker DM, Hagspiel KD, et al. The role of spiral volumetric computed tomography in the diagnosis of pulmonary embolism. *Arch Intern Med* 2000; 160:293–298
- 100 Bates SM, Ginsberg JS. Helical computed tomography and the diagnosis of pulmonary embolism. *Ann Intern Med* 2000; 132:240–241
- 101 Gefter WB, Hatabu H, Holland GA, et al. Pulmonary thromboembolism: recent developments in diagnosis with CT and MRU imaging. *Radiology* 1995; 197:561–574
- 102 Kim K, Muller NL, Mayo JR. Clinically suspected pulmonary embolism: utility of spiral CT. *Radiology* 1999; 210: 693–697